The Potential of Point-of-Care Digital Tomosynthesis in an Intensive Care Setting

Summary

Today, bedside imaging of critically ill patients in an Intensive Care Unit (ICU) relies on Anterior-Posterior Chest X-rays. However, obtaining high quality images is a challenge which is compounded by the lack of depth information. The option of obtaining 3D images in the form of Digital Tomosynthesis on a mobile X-ray system would overcome many challenges of planar X-ray in general and bedside mobile imaging in particular. Adaptix's distributed flat panel X-ray source (FPS) allows the development of a compact, lightweight point-of-care imaging device that would enable bedside 3D imaging whenever and wherever needed. Such a device could dramatically increase diagnostic and therapeutic confidence and potentially reduce the number of CT examinations required, thereby avoiding the risks of transporting patients outside the ICU environment.

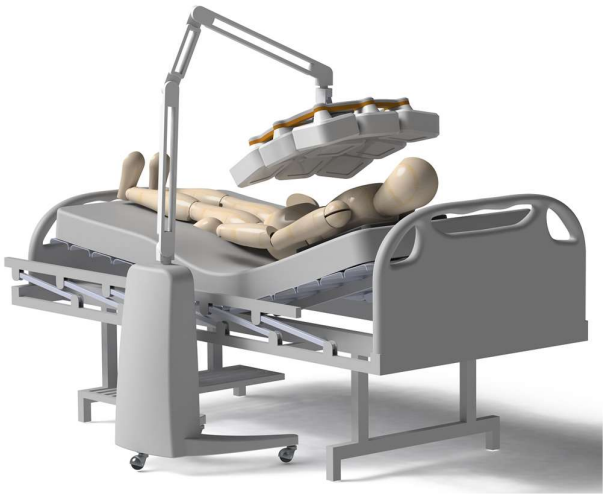

Clinical Challenge

Limitations of mobile planar chest X-ray

Planar chest X-ray (CXR) plays an instrumental role in managing critically ill patients. In addition to diagnosing and monitoring a wide range of cardiopulmonary disorders, CXR is used to ensure appropriate positioning and detect potential complications of intrathoracic medical devices such as central venous catheters (CVC) or nasogastric feeding tubes (NGT) (Refs 1-2, 5, 8-10). The American College of Radiology (ACR) recommends performing a chest radiograph, 1) after placement of equipment such as an endotracheal tube, CVC, NGT etc, 2) when the condition of the patients deteriorates or, 3) initially for patients who are admitted to the ICU for cardiac monitoring or extrathoracic disease. Daily CXR is indicated for patients with acute cardiopulmonary problems and patients on mechanical ventilation (4,9,11-12).

As critically ill patients are less mobile, bedside anterior-posterior (AP) CXR is the imaging modality of choice. There are diagnostic limitations of a portable CXR of a supine patient compared to standard posterior-anterior (PA) CXR on an erect patient. An AP chest exam of a supine patient demonstrates a magnified heart due to the shorter Source-Image Distance (SID) compared to a standard PA CXR (Figure 1). The enlarged heart shadow potentially obscures retrocardiac structures and challenges the assessment of cardiac size. Since the air-fluid levels and meniscus signs cannot be seen in supine patients, certain conditions such as pleural effusions are more difficult to diagnose. Given the status of many ICU patients, optimal patient positioning and preparation is challenging - resulting in rotated patient positions, additional superimposition of anatomical structures (such as clavicles over apical lung), insufficient inspiration and motion artefacts. Superimposition of life supporting devices (either inside or on the patient) further reduce the quality of the portable CXR in the ICU. Most portable units acquire images using a voltage of circa 90 kV without the use of an anti-scatter grid instead of the standard 120 kV used in PA CXR, so the resulting images present with a less clear appearance of the ribs and a suboptimal image contrast (Refs 3, 6-7).

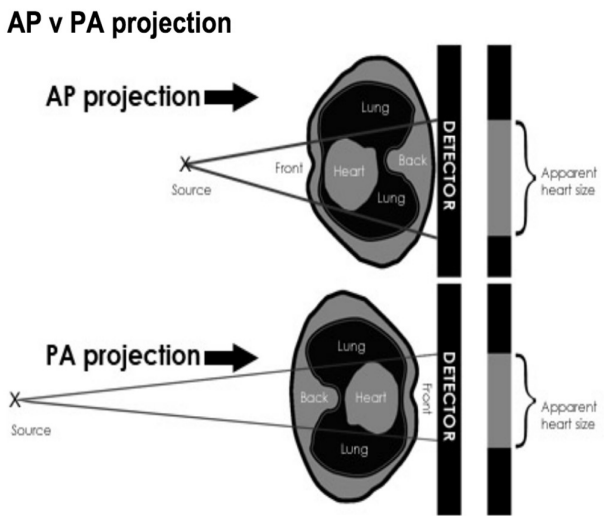

Figure 1) The effect of projection direction and SID on the apparent heart size
Image: https://www.radiologymasterclass.co.uk

Complications of using CT for ICU patients

Computerized Tomography (CT) scanning would be better suited to detect, characterize and quantify pulmonary parenchymal and pleural space disease and localize the position of medical devices in the patient. In particular, when CXR is inconclusive or does not correlate with the clinical situation, CT can improve diagnostic accuracy and affect treatment decisions for example in conditions such as empyema, lung abscess, mediastinal abscess and pleural effusion (5,14-15). In patients on mechanical ventilation, up to 40% of pneumothorax (PTX), 70% of bullae, and 80% of pneumomediastinum are not seen on CXR, only on CT. Also, CT is able to detect unsuspected PTX in 7% of ventilated patients (5, 16-17). A retrospective study from 2015 concluded that in circa 25% of the patients of a Medical Intensive Care Unit, the CT findings changed the therapeutic management (19).

In addition to the higher radiation exposure and higher procedure costs compared to CXR, CT scanners are in general located in the Radiology Department (RD) and not at the ICU - hence a critically ill and therefore fragile patient will have to be transported from the ICU to the RD and back. Intra-hospital transport, from the ICU to the RD, is complicated and poses a high risk to critically ill patients. They require provision of several highly qualified staff, specially designed transport equipment, as well as continuous monitoring and can take up several hours. Various authors looked into the likelihood of adverse events during an intra-hospital transport of ICU patient, and the pooled data allowed the conclusion that adverse events (major and minor) occurred in up to 71% of the intra-hospital transports (13,18).

This paper introduces a new technology which seeks to address some of these shortcomings.

Options for bringing 3D to the ICU

Digital Tomosynthesis - State of the Art

Digital Tomosynthesis (DT) is a limited-angle tomography where a motorised X-ray source moves relative to a (usually) stationary detector (Figure 2). Usually, between 30-60 low-dose X-ray projections are acquired and reconstructed into coronal images. Those have a higher in-plane resolution than CT images, but due to the limited sweep angle, a lower depth resolution. As a 3D imaging modality, DT removes the obscuring effect of overlapping anatomical structures and can provide more diagnostic accuracy than a simple 2D planar X-ray (21-23). DT demonstrated a significant potential to reduce utilisation of CT and therefore to reduce patient X-ray exposure, time to diagnosis, and imaging costs, in particular in patients with inconclusive CXR findings (20). Current DT systems are wall mounted, heavy and not mobile, hence do not allow bedside imaging (3).

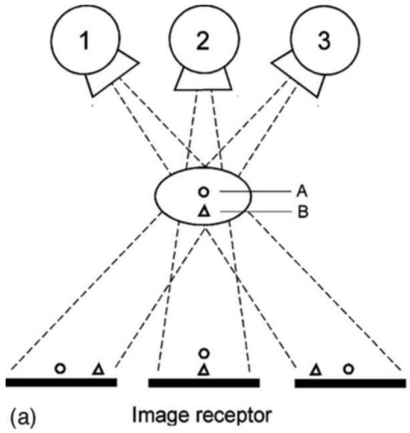

Figure 2: Different positions (1-3) of a moving X-ray Source in a DT system
(Dobbins, JT: Tomosynthesis imaging: At a translational crossroads, Med. Phys. 36 (6), June 2009).

Simulation of Bedside Digital Tomosynthesis using conventional X-ray sources

Adding the capability to perform chest DT exam to a portable CXR system would increase the diagnostic accuracy of point-of-care imaging in the ICU and reduce the number of risky and time consuming trips to a CT scanner. However, currently there are no existing portable DT devices.

Cant et al. (3) recently published encouraging results of a proof-of concept study, where DT exams of supine ICU patients were simulated using CT scans. The images of two ICU patients who had received a CXR showing abnormal findings and then a subsequent chest CT within one hour, were used to compute 15 DT projections by applying a linear forward projection of the CT volume onto a virtual flat panel detector. The reconstructed simulated DT images were compared to the original CXR. In addition, a simulated DT of an anthropomorphic chest phantom was compared with a dataset that was acquired from the same phantom, using a commercially available mobile X-ray unit (90 kVp and 0.1 mAs), which was moved by hand. The simulated and manually acquired DT projections were acquired from the same angles (angular range of 6°, total tube travel distance to 14 cm) and source image distance (120 cm) and reconstructed to 55 coronal slices, with a depth of 5 mm each. For both patients, the simulated DT discovered clinically relevant abnormalities (bilateral pneumothorax and retrocardiac consolidation, volume of pneumomediastinum) that were not clearly visible in the CXR. When comparing the simulated images with the manually acquired images of the chest phantom, both datasets showed similar structures and level of resolution. The authors concluded that the presented data shows the potential of portable DT in improving the diagnostic accuracy and therefore patient management of bedside imaging in ICU patients.

Potential of a Flat Panel Source (FPS) for Bedside DT imaging

As described elsewhere (24), Adaptix Imaging is developing a distributed flat panel X-ray source (FPS) to create lower-cost, smaller footprint, higher performance and compact DT devices that can be used for bedside imaging. The FPS sequentially triggers low-dose X-ray emissions from different positions without the need to mechanically move the X-ray source. The acquired projections are reconstructed into a 3D DT volume and a complementary synthetic 2D image. A stationary source avoids the cost of precision motors, reduces motion artifacts and allows shorter acquisition times. As the geometry of the emitted beams allows the source to be closer to the patient (Figure 3), and many ultra-low dose sequential emissions are made rather than a single high-dose emission, the required input power is dramatically less than for a conventional X-ray system. The device can be operated from a standard power supply. The dose to the patient would be similar to planar X-ray and substantially less than CT.

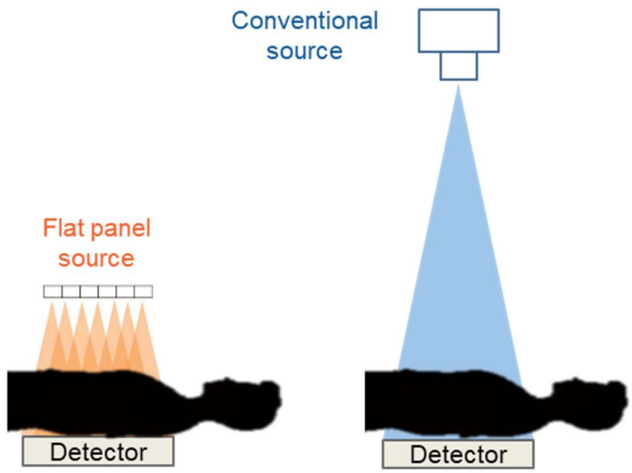

Figure 3: Differences in beam geometry and SID between a conventional X-ray tube and a FPS. The latter is ideal for mobile imaging as it allows creation of a compact device using standard power supply, and without substantial organ magnification.

Advantages of FPS-based point of care DT

Adaptix's reconstruction algorithm will produce a 3D DT dataset and a synthetic 2D image from the same exam, as is done in modern Breast Tomosynthesis devices (25). In contrast to the Cant et al. (3) conceptual study already discussed, the Adaptix device will acquire projections over a 30-40° angle, resulting in an improved depth resolution. The faster, stationary acquisition compared to any conventional DT system reduces the likelihood of motion artifacts.

Whereas most mobile 2D X-ray carts require motorization and heavy batteries, a system using Adaptix's FPS would not need a motor and could be operated from a standard power line. Dependent on the final configuration, the device would weigh circa 50kgs – compared to 100 – 600 kgs for conventional 2D systems. The smaller footprint and compact design would facilitate imaging in an already crowded ICU department.

Compared to a state-of-the-art AP mobile digital chest X-ray on a supine patient, we anticipate an FPS based point of care device would enhance the currently available point of care X-ray options in the following ways (Details in Table 1):

- Allow better localization of intrathoracic medical devices such as chest drainage tubes, NG tubes and others
- Avoid organ magnification
- Address organ and structure superposition due to suboptimal patient position
- Improve detection of pneumothorax due to 3D information
- Better identify and quantify lung consolidation
- Improve visualisation of intrathoracic structures
- Reduce scatter compared to 2D acquisitions without a grid
-

Alternative methods of stationary bedside DT imaging

A different type of novel X-ray sources that can potentially be used for bedside DT imaging are Carbon Nano Tubes (CNT). Arranged as a linear array, the individual CNTs emit radiation sequentially in order to acquire projections from different angles. Similar to the distributed FPS, this concept also allows acquisition of a DT dataset without physical movement of the source. In contrast to the discussed distributed FPS however, the geometry of the emitted beam will still require a longer SID, similar to conventional DT systems. Initial studies with a prototype reported an SID of 130 cm for supine chest imaging, which would translate into a larger and less compact device for mobile imaging (27,28). Another publication looked into a distributed X-ray source using photocathodes where the emission was triggered by an incoming UV photon. Despite promising images of a pig lung, this solution is currently limited to energies up to 40 kVp, which is unlikely sufficient for chest imaging in humans (29).

Potential further applications

Once established for adult patients - a similar concept with a smaller source and lower energy could be applied to neonatal imaging. Similar to adult patients, premature babies and newborns in a Neonatal Intensive Care Unit (NICU) are often in a fragile state and any transport to the radiology department would be challenging and time-consuming at least. The diagnosis of a Necrotising Enterocolitis (NEC) - a gastrointestinal condition in preterm infants which is potentially life-threatening - requires an AP view and often additional left-lateral decubitus views (LLDP). The latter includes repositioning the neonate onto their side, which may not be tolerated well by the neonate, especially when they are ventilated (26). Other situations that would require lateral positions include the detection of free air abdominal air, pneumothorax or the verification of the correct position of an Peripherally Inserted Central Catheter (PICC). Having the option of low-dose, mobile 3D imaging available would often allow to image neonates without repositioning them while increasing the diagnostic confidence.

In addition to imaging critically ill patients in an ICU environment, the Adaptix device would be beneficial for elucidating hilar and mediastinal masses; for example in nursing homes, emergency rooms or field medicine. Even with only one X-ray energy setting for DT, the device could also be used to image other body parts such as hips and potentially abdomen.

Table 1 - Advantages of point of care chest DT compared to bedside AP supine X-ray and conventional DT

Challenge of supine 2D AP in ICU	Source of the challenge	Benefits of FPS-based bedside DT
Magnified heart shape and widened mediastinum	Heart anterior organ, short SID increases magnification	No organ magnification Retro-cardiac space visible Lower risk of motion artifacts compared to conventional DT
Lung fields are shortened	Patient position, insufficient inspiration	No tissue superimposition Less breathing artifacts due to short acquisition compared to conventional DT No artifacts due to suboptimal source movement compared to conventional DT
Ribs may appear more horizontal, clavicules projected higher up	Patient position	No tissue superimposition Less breathing artifacts due to short acquisition compared to conventional DT No artifacts due to suboptimal source movement compared to conventional DT
Air-fluid levels are not seen	Supine position, air and fluid level perpendicular to X-ray beam	No tissue superimposition Better discrimination between air and fluids in between the different slices Quantification of effusions and other consolidations
Scapulae are not retracted laterally, they remain projected over lung	Arm position	Less breathing artifacts than conventional DT No artifacts due to suboptimal source movement compared to conventional DT No tissue superimposition
Asymmetric Images	Patient position and missing compliance	Less breathing artifacts than conventional DT No artifacts due to suboptimal source movement compared to conventional DT No tissue superimposition
Ribs less translucent than in standard X-ray	Lower kVp causes higher beam attenuation the skeleton and therefore less visibility of internal structures	Missing tissue superimposition due to 3D imaging improves visualization of thoracic cavity
More superposition of anatomical structures	Nature of 2D exam, patient position and compliance	No tissue superimposition Less breathing artifacts than conventional DT No artifacts due to suboptimal source movement compared to conventional DT Wider angular range likely to result in better ability to follow vessels through the volume
Reduced Image contrast	No anti-scatter grid and fewer options for correction using 2D data	Sophisticated scatter suppression reconstruction possible with 3D data.

Literature

1. Godoy, MCB et al: Chest Radiography in the ICU: Part 1, Evaluation of Airway, Enteric, and Pleural Tubes, AJR, 2012; 198:563–571
2. Godoy, MCB et al: Chest Radiography in the ICU: Part 2, Evaluation of Cardiovascular Lines and Other Devices, AJR, 2012; 198:572–581
3. Cant, J et al: Can portable tomosynthesis improve the diagnostic value of bedside chest X-ray in the intensive care unit? A proof of concept study. European Radiology Experimental, 2017 1:20
4. ACR: American College of Radiology: ACR Appropriateness Criteria, Intensive Care Unit, 1995 (Last review 2014)
5. Fishman, JE et al: Thoracic imaging in the intensive care unit, Applied Radiology, 2005
6. https://www.radiologymasterclass.co.uk, Tutorial Chest X-ray Quality
7. www.wikiradiography.net
8. Bekemeyer, WB et al: Efficacy of chest radiography in a respiratory intensive care unit: A prospective study. Chest, 1985; 88:691-696.
9. Greenbaum, DM et al: The value of routine daily chest x-rays in intubated patients in the medical intensive care unit. Crit Care Med, 1982; 10:29-30.
10. Henschke, CI et al: Bedside chest radiography: Diagnostic efficacy. Radiology, 1983; 149:23-26.
11. Marik, PE et al: The impact of routine chest radiography on ICU management decisions: An observational study. Am J Crit Care, 1997; 6:95-98.
12. Chahine-Malus, N et al: Utility of routine chest radiographs in a medical-surgical intensive care unit: A quality assurance survey. Crit Care, 2001; 5:271-275.
13. Ott, LK et al: Intrahospital Transport to the Radiology Department: Risk for Adverse Events, Nursing Surveillance, Utilization of a MET and Practice Implications. J Radiol Nurs, 2011; Jun;30(2):49-52.
14. Miller, WT Jr et al:Thoracic CT in the intensive care unit: assessment of clinical usefulness. Radiology, 1998; Nov;209(2):491-8.
15. Snow, N et al: Thoracic CT scanning in critically ill patients. Information obtained frequently alters management. Chest, 1990; Jun;97(6):1467-70
16. Mirvis, SE et al: Thoracic CT in detecting occult disease in critically ill patients. AJR, 1987; 148:685-689.
17. Miller WT Sr.: The chest radiograph in the intensive care unit. Semin Roentgenol. 1997; 32(2):89-101
18. Blakeman TC et al: Inter- and Intra-hospital Transport of the Critically Ill. Respiratory Care June 2013; 58(6):1008-1023
19. Awerbuch, E. et al: The Impact of Computed Tomography of the Chest on the Management of Patients in a Medical Intensive Care Unit, J Intensive Care Med, 2014; 30(8):505-511
20. Quaia, E.: Digital tomosynthesis as a problem-solving imaging technique to confirm or exclude potential thoracic lesions based on chest X-ray radiography. Acad Radiol, 2013; 20:546-53
21. Dobbins, JT et al: Digital tomosynthesis of the chest. J Thorac Imaging, 2008; 23:86–92
22. Chou, S et al: Digital tomosynthesis of the chest: current and emerging applications. Radiographics, 2014; 34: 359–372
23. Dobbins, JT: Tomosynthesis imaging: At a translational crossroads. Med Phys, 2009, 36(6): 1956-67
24. Schmiedehausen, K et al: The Potential Clinical and Economic Impact of Chest Digital Tomosynthesis using Stationary Distributed X-ray Sources, Adaptix Clinical White Paper (2018)
25. Zuckermann, SP et al: Imaging With Synthesized 2D Mammography: Differences, Advantages, and Pitfalls Compared With Digital Mammography American Journal of Roentgenology, 2017; 209:222-229
26. Hunt, Kristin N: The NICU: Environmental Effects of the Neonatal Intensive Care Unit on Infants and Caregivers 2011; Research Papers; Paper 71
27. Gunnell, ET et al: Initial clinical evaluation of stationary digital chest tomosynthesis in adult patients with cystic fibrosis. Eur Radiol, 2018 Sep 25
28. Gunnell, ET et al: Comparison of Stationary Digital Chest Tomosynthesis to Portable Chest Radiographs: A Patient Study. Abstract RSNA 2018
29. Cramer, A et al: Stationary Computed Tomography for Space and other Resource - constrained Environments. Scientific Reports, 2018 8:14195

Glossary:

CXR - Chest X-ray
ICU - Intensive Care Unit
CVC - Central Venous Catheter
NGT- Nasogastric Tube
ACR - American College of Radiology
PA - Posterior Anterior
AP - Anterior Posterior
LAT - Lateral
SID - Source-Image Distance (from source to detector)
CT- Computerized Tomography
PTX - Pneumothorax
RD - Radiology Department
DT - Digital Tomography
FPS - Flat Panel Source
NICU - Neonatal Intensive Care Unit
NEC - Necrotising Enterocolitis
PICC - Peripherally Inserted Central Catheter
LLDP - Left Lateral Decubitus Position